

10

AMPUTATIONS

SCENARIO

LOWER EXTREMITY AMPUTATIONS

SPECIFIC TECHNICAL CONSIDERATIONS

UPPER EXTREMITY AMPUTATIONS

SPECIAL CONSIDERATIONS

COMPLICATIONS OF AMPUTATION

KEY MESSAGES REGARDING AMPUTATION

SUGGESTED RESOURCES

REFERENCES

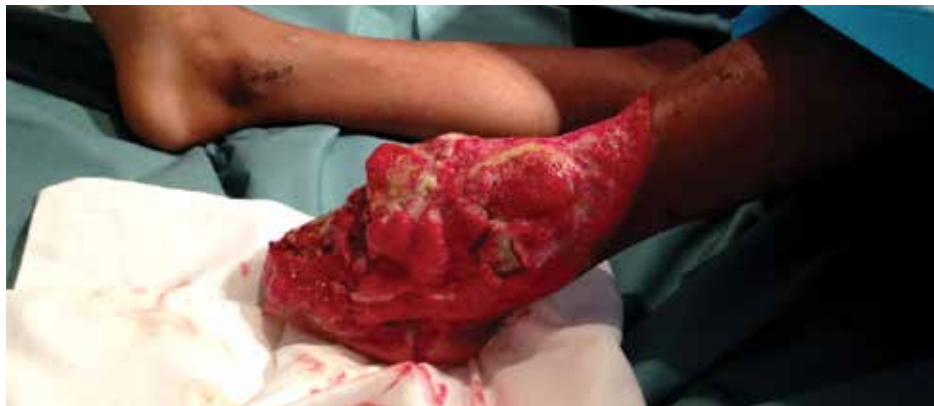

Figure 1. Traumatic Amputation of the left leg (Bar-On)

SCENARIO

A 20-year-old female was a victim of blast injury to her right lower leg four hours prior to presentation at an EMT type 1.

There is soft tissue loss over the anterior aspect of the ankle with loss of the tibial pilon and exposed fragments of bone from the distal tibia. In the foot there are no palpable pulses, with very slow capillary refill. There is no sensation over the plantar aspect of the foot.

After washout, dressing, and splinting the patient arrives at an EMT type 2, twelve hours later. No tourniquet was applied but the patient's toes are now cyanotic and there is no longer capillary refill. An amputation is recommended but the patient's husband categorically refuses to consent.



TYPE 1

- Management of injuries that may require amputation at type 1 facilities primarily consists of wound care, analgesia, possible tourniquet placement to stop life threatening hemorrhage and transfer to a higher level facility. Patients with vascular compromise should have a high priority for transfer.



TYPE 2

- Amputation is a surgical and reconstructive procedure that is a last resort. Evaluation by experts at type 2 and 3 facilities to assess for possible options for limb salvage should be obtained whenever possible.



TYPE 3

SPECIAL CONTEXTS

- » The case scenario discussed at the opening of this chapter is, unfortunately, not uncommon. Amputation is not just a surgical procedure, it is a process through which the patient, the patient's family, and the entire social circle must navigate for the remainder of the patient's life.
- » The decision to amputate must take into account socio-cultural, religious, economic and ethical dimensions.
- » In many places an insensate and useless, even painful, limb is preferred to an amputation. Young male amputees may never work, young female amputees may never marry.
- » The humanitarian community has been criticized recently for having too low a threshold to amputate, particularly following the 2010 earthquake in Haiti.
- » The various scoring systems used to predict the need for amputation may not be applicable in disaster and austere settings.
- » The availability of reconstructive surgery should be taken into account when planning the treatment.

GENERAL CONSIDERATIONS

- » The amputation stump should be painless, well padded, balanced, and easy to fit with a prosthesis.
- » Prosthetics should be comfortable, light, durable and built from locally available materials by local prosthetists.
- » Upper extremity amputees always lose some degree of function, and social reintegration may be compromised where much of the work is manual in nature.
- » Loss of function in lower extremity amputees depends largely on the prosthetics and rehabilitation capacity of the local system.
- » In the absence of an appropriate prosthesis, lower extremity amputees can move only with assistive devices that occupy both upper extremities.

KEY POINT

- » **Amputations should never be performed without the written and witnessed consent of the patient and/or guardian, and when possible, additional family members should be included in the decision process.**
- » **Photographic evidence and a second opinion should be obtained when possible in order to strengthen the documentation.**

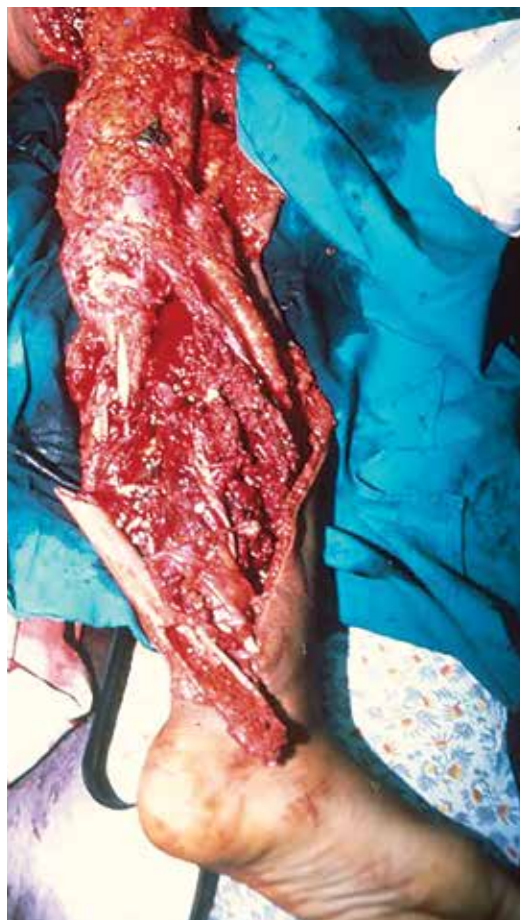

Figure 2. Severe soft tissue damage and open fracture of the lower limb that required amputation (*Bar-On*)

CONTROVERSY!

There is disagreement among surgeons as to whether the local prosthetics and rehabilitation capacity should dictate the level and type of an amputation. Some advocate always taking these factors into account, while others feel that in conflicts and SODs it is often impossible to know what services may be present in the months and years ahead.

KEY POINT

Principles of Amputation in conflict and disasters

- » Guillotine amputation is almost never indicated except as a last resort to extricate an entrapped patient.
- » Preserve limb length
- » Use flaps of convenience

GENERAL PRINCIPLES

- » The definitive indications for amputation are:
 - Avascular limb in the absence of vascular reconstruction capabilities
 - Uncontrollable infection
 - Mangled extremity in the absence of reconstructive capabilities
- » Even in disaster management settings, amputations can generally be delayed except in the case of severe wounds that are complex, infected, contaminated, or have no viable distal tissues.

- » The principles of wound debridement apply when performing an amputation: remove all devitalized tissues, leave as much skin as possible for flaps, and create as long a stump as possible.
- » A pneumatic tourniquet should be used if available. Care should be taken to deflate tourniquet prior to flap closure to ensure adequate haemostasis of the lower limb.
- » Named vessels should be ligated individually with transfixing sutures.
- » Nerves should be sharply transected under gentle traction, allowing the tip of the nerve to retract or be buried in the muscle belly.
- » When selecting the level, remember that a short stump that preserves a joint is preferable to a more proximal amputation.
- » A disarticulation is preferable to a more proximal through the bone amputation, as the stump end is already a weight bearing surface and prosthetic fitting has improved with more modern techniques and materials.

DELAYED CLOSURE

- » The amputation stump should be treated as any other wound and never closed primarily.
- » Delayed primary closure of the amputation stump should be attempted when the wound is clean, usually 2-5 days following the initial operation.
- » If needed, stumps can be partially closed and allowed to heal by secondary intention. Additional options include skin grafts or flaps.
- » Efforts to preserve maximum limb length are not always successful. However, bone ends should always have adequate soft tissue coverage. Bone shortening is preferable to inadequate soft tissue padding of the stump end.

PITFALL

NEVER put a pillow directly under the knee joint of a BKA patient.

NURSING, REHABILITATION AND PHYSIOTHERAPY

- » Prevention of joint contractures is of paramount importance.
- » For above-knee-amputations (AKA) flexion and abduction contractures can be prevented through proper surgical technique and early active and passive physiotherapy.
- » The AKA patient should lie prone for several hours each day.
- » For below-knee-amputations (BKA), knee flexion contracture is a major concern. It can be prevented by splinting the joint in extension until the time of DPC or having the closed stump rest on a pillow

KEY POINT

CULTURAL CONTEXT

- » Ensure that proper arrangements are made for the disposal of an amputated limb. These practices will vary between cultures and religions.

SPECIFIC TECHNICAL CONSIDERATIONS

FOOT AMPUTATIONS – When feasible, toe, ray, and trans-metatarsal amputations result in a sensate and weight bearing stump and should be employed when possible.

- » More proximal amputations rely on the preservation of the high quality heel pad and balancing the opposing dorsal and plantar flexors.
- » Mid-tarsal amputations are not recommended.
- » If the heel pad is intact a calcaneo-talo-tibial fusion can provide a stable weight bearing stump.

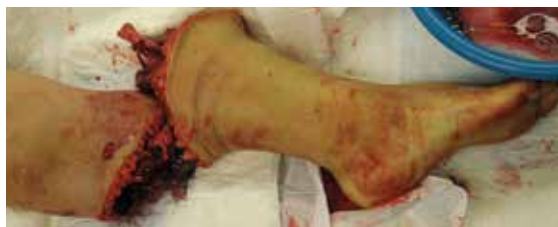

Figure 3. Severe injury with no chance of re-implantation is an indication for amputation. (Bar-On)

KEY POINT

- » If the heel pad is lost, severely damaged or missing then a distal BKA should be undertaken.

ANKLE DISARTICULATION – Syme amputation often provides the best result if an ankle disarticulation is required. The procedure provides an end bearing stump.

- » The procedure requires an intact heel pad which is secured to the distal tibia anteriorly with trans-osseous sutures.

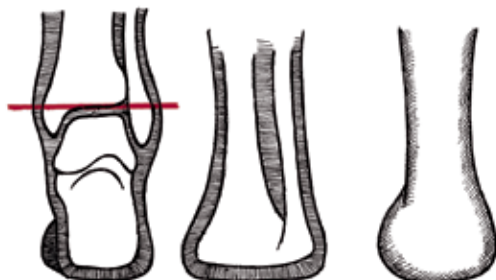


Figure 4. Line diagram of a Syme amputation. This technique utilizes an intact heel pad to provide patients with a stable weight bearing stump. The operation preserves the physal plate and can be fitted with a prosthesis for aesthetic reasons. (ICRC)

CONTROVERSY!

Many surgeons prefer excising the talus and doing a tibio-calcaneal fusion to a tibio-talo-calcaneal fusion. However, other surgeons feel that in austere conditions fusions should be avoided due to risks of infection and non-union and a Syme amputation may be preferable.

TRANS-TIBIAL AMPUTATIONS – BKA is the most common amputation performed in most disaster settings. The classic Burgess step cut is often not possible, however less orthodox stumps can still provide excellent results.

- » The distal $\frac{1}{3}$ of the tibia is not useful in weight bearing, but the stump should be left as long as possible up to this point.
- » Proximally, amputation less than 6 cm below the tibial tubercle will often require conversion to a knee disarticulation.
- » The anterior tibial crest should be beveled at a 45 degree angle and the edges smoothed with a rasp.
- » The fibula should be 1.5 - 2 centimetres shorter than the tibia, and the deep posterior fascia sutured to the anterior aspect of the tibia.
- » Skin should be closed over a drain in an interrupted fashion, with care taken to avoid “dog-eared” skin edges.
- » The stump should be splinted in extension and rehabilitation begun as soon as possible.

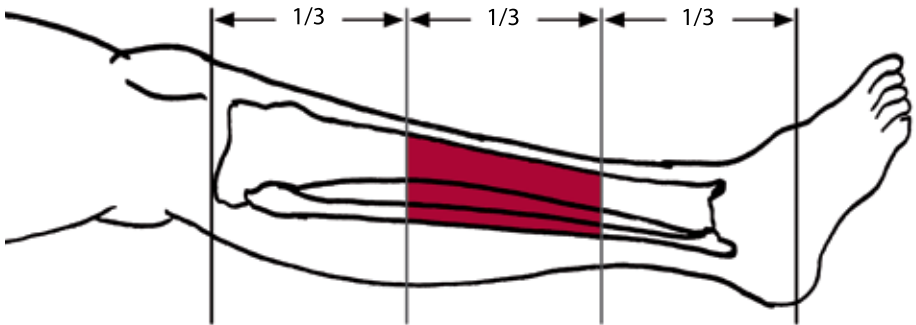


Figure 5. ICRC illustration of the ideal stump length for BKA, emphasizing the fact that the middle third of the tibia makes for the ideal stump. (ICRC)

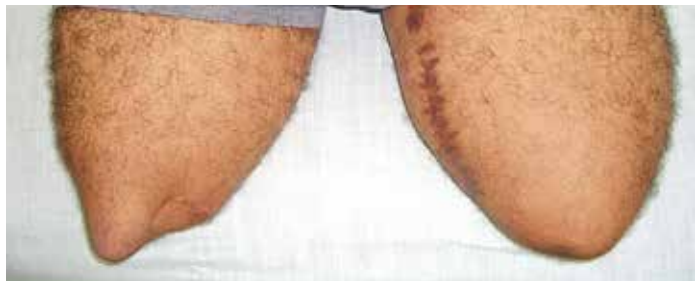KNEE DISARTICULATION – This procedure produces a sturdy end-bearing stump. In the past technical problems with the prosthetic knee joint have discouraged its use. However, recent technical advances in materials and prosthetics can allow prosthetists to address this issue, even in austere environments.

- » Closure of knee-disarticulation incisions utilizes a standard fish mouth incision with patellar tendon sutured to the posterior cruciate ligament posteriorly.

TRANS-FEMORAL AMPUTATIONS – Trans-Femoral or above knee amputations (AKA) are the second most common amputation that requires cutting a long bone. These stumps, like BKAs are not end bearing and must be contact fitted.

- » The femur is usually cut at or near the distal metaphyso-diaphyseal junction in a transverse fashion.
- » The key to successful AKA requires appropriate balancing of agonistic and antagonistic forces, as amputations at the mid or distal femoral shaft are at risk of developing an abduction contracture of the hip from an unopposed gluteus medius.
- » The belly of the adductor magnus is cut at or near Hunter’s canal and fixed on the lateral side of the femur, preferably with trans-osseous sutures. This maneuver serves to counteract the abductor forces. The quadriceps is attached posteriorly in a similar fashion.
- » The suturing of the quadriceps directly to the hamstring should be avoided as it can create a “slinging” effect over the bone end that is painful.
- » Amputations through the proximal 1/3 of the femur are at risk of developing a flexion contracture from unopposed actions of the psoas muscle. To prevent this every effort should be made to keep or reattach the gluteus muscle to the linea aspera posteriorly.
- » Hip disarticulation and pubo-sacro-iliac disarticulation are rare procedures and should be reserved for instances in which no other procedure is possible.

Figure 6. Image demonstrating the importance of good soft tissue covering. The left stump is well covered, the right is lacking. (ICRC)



UPPER EXTREMITY AMPUTATIONS

HAND INJURY

- » Hand function is precious and every millimeter of movement and length is of high value. Therefore, debridement should be as conservative as possible and every effort made to preserve the maximum number of digits, particularly the thumb.
- » A small phalangeal stump provides better function than a metacarpal phalangeal disarticulation.
- » K wires can be used to stabilize fractures, and second look operations should be utilized whenever possible in order to allow dead tissue to declare itself.
- » Dressings should consist of absorbent, fluffy, dry dressings that allow for visualization of the finger tips.
- » If a wrist disarticulation is required the thicker palmar skin should be used to cover the stump.
- » There are a multitude of coverage techniques that can prove to be digit-saving (V-Y advancement flaps, finger to finger flaps, hand in belly technique).

ARM INJURY

- » **Forearm Amputations** – the longer the stump of forearm preserved, the higher degree of pronation and supination function will be preserved.
- » The radius and ulna should be amputated at the same level. There are no indications for the Krukenberg or “lobster claw” technique.
- » An elbow disarticulation is preferable to a through the humerus amputation.
- » **Upper Arm Amputations** – amputations through the distal half of humerus allow for pinching between the arm and chest.
- » Proximal amputations often result in an abduction contracture that limits functionality.
- » Shoulder disarticulation and scapula-thoracic disarticulation should not be considered except in instances of life-saving emergency surgery.
- » All upper extremity amputees must start rehabilitation as soon as possible.
- » In resource poor environments basic prostheses are normally available.
- » Patients often require only a cosmetic hand or no prosthesis at all.

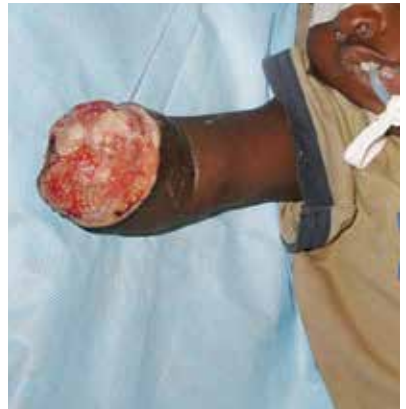

Figure 7. Upper extremity amputation in a young patient . (Bar-On)

PAEDIATRIC CONSIDERATIONS

- » If the physal plate is intact, the limb will continue to grow. Therefore, bone resection in children should be very conservative.
- » In children, disarticulations do better than through the bone amputations, due to the fact that exostosis and overgrowth are common with AKA and BKA.
- » If possible, a long periosteal sleeve should be preserved and sutured to itself over the bone end.
- » The open bone end should be “capped” by plugging the open medullary cavity with a piece of bone harvested from the amputated segment.

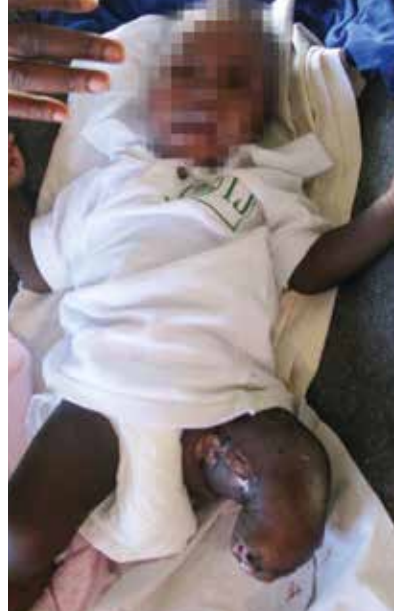

Figure 8. Amputations in children require special attention due to the fact that the bones are often still capable of growth. (Bar-On)

KEY POINT

Mangled Extremity

- » In the event of mangled extremities, the distal extremity should be amputated as if it were an isolated problem and proximal fractures treated as if they were an isolated problem (i.e. fix with sling, external fixation, or traction).
- » **DO NOT** amputate through the fracture.

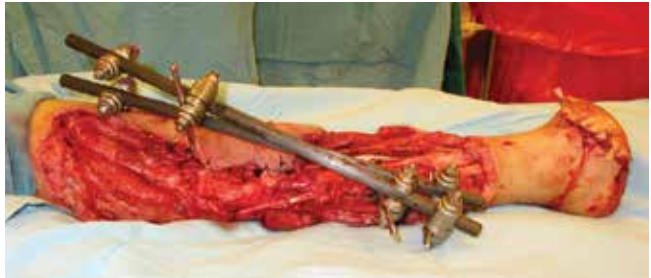

Figure 9. In the event of mangled extremities (or beyond classification trauma), proximal and distal injuries should be dealt with separately whenever possible (Bar-On)

WOUND ISSUES COMPLICATIONS

- » Acute wound dehiscence and necrosis occur if the wound is sutured under excess tension. This can be prevented by leaving the wound open, wrapping the stump and revisiting the wound when swelling has decreased.
- » Negative pressure dressings are a very effective means of shaping a stump and reducing swelling.
- » Purulent drainage means that necrotic material has been left behind and the wound requires re-bridement. Unless the infection is very superficial, antibiotics alone will prove inadequate.
- » Chronic wounds over bony prominences occur due to poorly shaped or padded stumps, due to excessive pressure in the prosthesis. Prosthetic modification may circumvent the problem, but stump revision is often necessary.

CONTRACTURES

- » Contractures develop when surgical balance of agonistic and antagonistic forces is not achieved or when appropriate rehabilitation capacity is not present. They can be prevented by physiotherapy, splinting, or casting.
- » Equinus contracture of the ankle or flexion contracture of the knee can be particularly crippling and are more easily prevented than treated. They require surgical release when they are rigid.

NEUROMAS

- » Neuromas occur on transected nerves as part of the physiologic process of repair. Painful neuromas are often transient but some never disappear. They can prove difficult to differentiate from phantom limb pain.
- » Pain due to neuromas occurs in the stump rather than the amputated limb, and can worsen with prosthetic use. Diagnostic blocks can be helpful in making the diagnosis.
- » If socket modification does not resolve the issue, surgical revision is indicated. The neuroma is resected and the neural stump allowed to retract proximally or buried in a muscle belly.

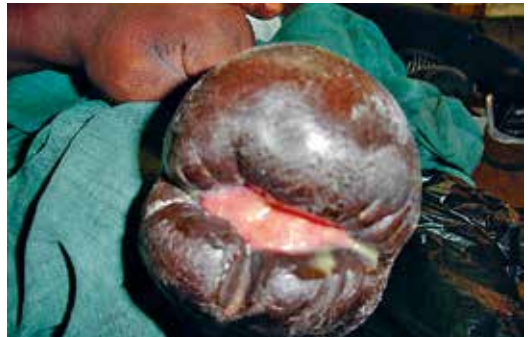

Figure 10. An infection of an amputation stump. (ICRC)

PHANTOM LIMB PAIN

- » Phantom pain is a common complication of limb amputation, occurring in nearly half of all amputees.
- » The pain is felt to be coming from the amputated segment rather than the stump itself.
- » It is commonly present at rest, but often worsens with the use of a prosthesis.
- » It can be difficult to fully differentiate from phantom sensation, a general sense by the amputee that the limb is still present. Phantom sensation generally disappears between 6 and 12 months post operatively.
- » Many techniques have been attempted to treat phantom pain, but tricyclic antidepressants and gabapentin have generally proven to be an effective regimen.

OVERGROWTH/EXOCYTOSIS

- » Overgrowth and osteophytes appear mainly in children, but can occur in adult patients when periosteal stripping has been overzealous. The pressure points generated by this condition often require surgical treatment of the overgrowth area.

MENTAL HEALTH

- » All patients in disasters and conflict sustain psychological as well as physical trauma. The additional trauma of undergoing an amputation can precipitate mental health problems such as depression, aggressiveness or substance abuse. The entire treatment team should be vigilant regarding these issues.

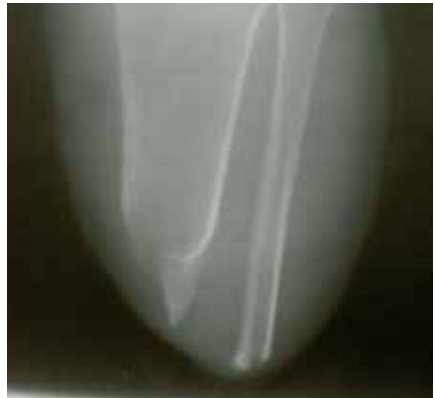

Figure 11. Osteophyte formation on the tibia, and overly long fibula causing pain and stump erosion in a BKA patient. (ICRC)

PROSTHESIS ISSUES

- » The amputee becomes a life long patient. A 20-year-old male with a 50 year life expectancy may require 20 different prostheses over the course of a lifetime. Maintenance, repair, replacement, and provision of soft goods all need to be provided for in a sustainable and durable manner.

KEY MESSAGES

- » Primary amputations are indicated if:
 - The extremity is not viable and revascularization is either not available or not indicated.
 - It is a life-saving procedure for treatment of an infection such as gas gangrene or decompensated systemic sepsis.
- » Amputations for indications other than those covered above can be performed in a delayed fashion.
- » No amputation should be performed at an EMT type 1 facility.
- » When discussing amputation with the patient and his or her family or support system, it is important to be very clear about the options and alternatives surrounding the operation. Give your best surgical advice and avoid giving unrealistic or false hope.
- » If possible obtain a second documented opinion and photographic documentation.
- » Never amputate without signed consent from the patient or guardian.
- » The viability of distal tissues should determine the indication for amputation, not the distal sensory or motor function or the presence of bone loss.
- » The amputation should always be as distal as is safely possible.
- » Do not primarily close the stump in disaster and conflict situations, plan for delayed primary closure at 2-5 days.
- » Never close the stump under tension, partial closure and repeat attempt at DPC is preferable to a high tension wound closure.
- » Be aware of the psychological repercussions for the patient and provide support as soon as possible.
- » Start physiotherapy and rehab as soon as possible.
- » Ensure that proper arrangements are made for the disposal of the amputated segment. The “proper arrangements” will vary across cultures.

SUGGESTED RESOURCES

1. Knowlton LM, Gosney JE, Chackungal S, et al. Consensus statements regarding the multidisciplinary care of limb amputation patients in disasters or humanitarian emergencies: report of the 2011 Humanitarian Action Summit Surgical Working Group on amputations following disasters or conflict. *Prehospital and Disaster Medicine* 2011; **26**(06): 438-48.

REFERENCES

2. Michael JW, Bowker JH. Atlas of amputations and limb deficiencies: surgical, prosthetic, and rehabilitation principles. American Academy of Orthopaedic Surgeons; 2004.
3. Giannou C, Balcan M. War surgery: Working with limited resources in armed conflict and other situations of violence. Volume 1. Geneva: International Committee of the Red Cross; 2009.
4. Giannou C, Balcan M. War surgery: Working with limited resources in armed conflict and other situations of violence. Volume 2. Geneva: International Committee of the Red Cross; 2009.
5. Gray R. War wounds: basic surgical management: the principles and practice of the surgical management of wounds produced by missiles or explosions. 1994.
6. Coupland RM. War wounds of limbs: surgical management. 1993.
7. Pasquina PF, Cooper RA. Care of the combat amputee. Government Printing Office; 2009.
8. Guidelines for the Care and Rehabilitation of Survivors. International Campaign to Ban Landmines—Working Group on Victim Assistance; 1999. http://www.essex.ac.uk/armagedcon/story_id/Guidelines%20for%20the%20care%20and%20Rehabilitation%20of%20Survivors.pdf (accessed 18 October 2016).
9. Smith DG, Wilson LS, conference chairs. Experts Reach Consensus on Amputation Techniques for War Injuries. *inMotion* 2003; 13(3). http://www.amputee-coalition.org/inmotion/may_jun_03/military.html.
10. Handicap International. The Rehabilitation of Amputees, Victims of Landmines. http://www.apminebanconvention.org/fileadmin/APMBC/IWP/SC_may06/speeches_va/Hi_Promotion_first_aid_9May06.pdf (accessed 18 October 2016).
11. Department of Veterans Affairs and Department of Defence Clinical Practice Guideline for Rehabilitation of Lower Limb Amputation. Online: Department of Veterans Affairs; 2007: 166.
12. World Health Organization. Best practice guidelines on emergency surgical care in disaster situations. World Health Organization; 2005.
13. Surgical care at the district hospital. World Health Organization; 2003.
14. AO Surgery Reference. 2016. (<https://www2.aofoundation.org/wps/portal/surgery2016>).
15. Norton I, Von Schreeb J, Aitken P, Herard P, Lajolo C. Classification and minimum standards for foreign medical teams in sudden onset disasters. Geneva: World Health Organization; 2013.

EMT Website: <https://extranet.who.int/emt/page/home>
 AO/ICRC/WHO Training Resources: <http://www.aofoundation.org/icrc>